

Soddo Christian Hospital Soddo, Ethiopia

Adelaide & Jerry Svoboda, April, 2018

Samaritan's Purse & World Medical
Mission



Samaritan's Purse



- Christian organization provides emergency aid to any with immediate physical needs.
- Found in >100 countries, incl. Somalia, Rwanda, Sudan, Iraq, Kosovo, Afghanistan, & Liberia.
- Begun in 1970, 90% of funds used for beneficiaries.



- World Medical Mission: the medical arm of Samaritan's Purse. Begun in 1977, by brother surgeons, Lowell & Richard Furman.
- WMM now supplies physicians, equipment, supplies, and bio-med technicians to 39 missionary hospitals in 24 countries (25 of the hospitals in 14 Afr. countries).

PAACS Surgical Residencies



- There are 3 surgeons for each 1 million Ethiopians.
- Pan-African Academy of Christian Surgeons.
- Begun in 1996: strategic approach to the paucity of surgeons in Africa.
- Spreading the gospel.

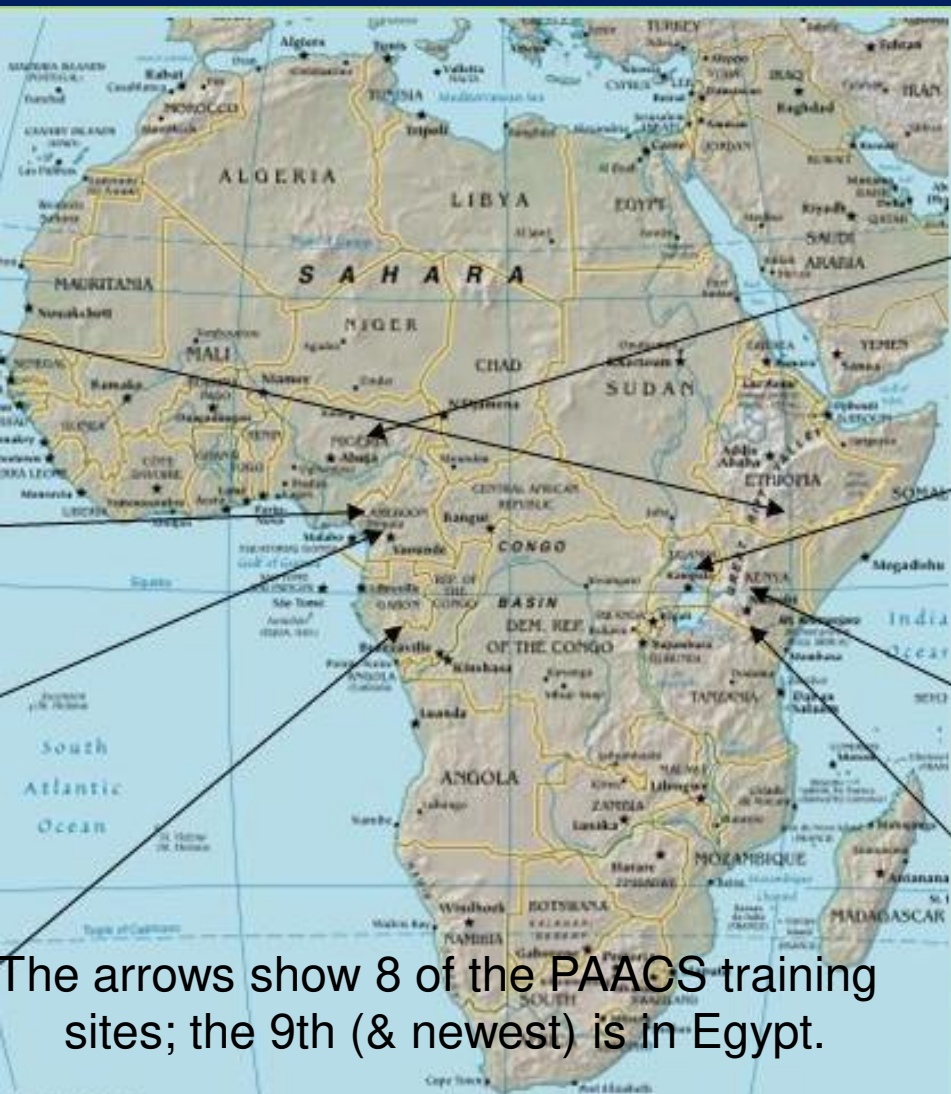Keir & Joanna Thelander



- God works any way He wants; we may not understand what He's up to at the time.
- We met them, with one babe in arms, at Bill & Susan Morehouse's in ~2006. They were on the way to Gabon.
- That year, Keir became a PAACS surgeon; by 2008, he was program director in Gabon; in 2016, he was named CMO of the PAACS residency system.

Location of PAACS training programs

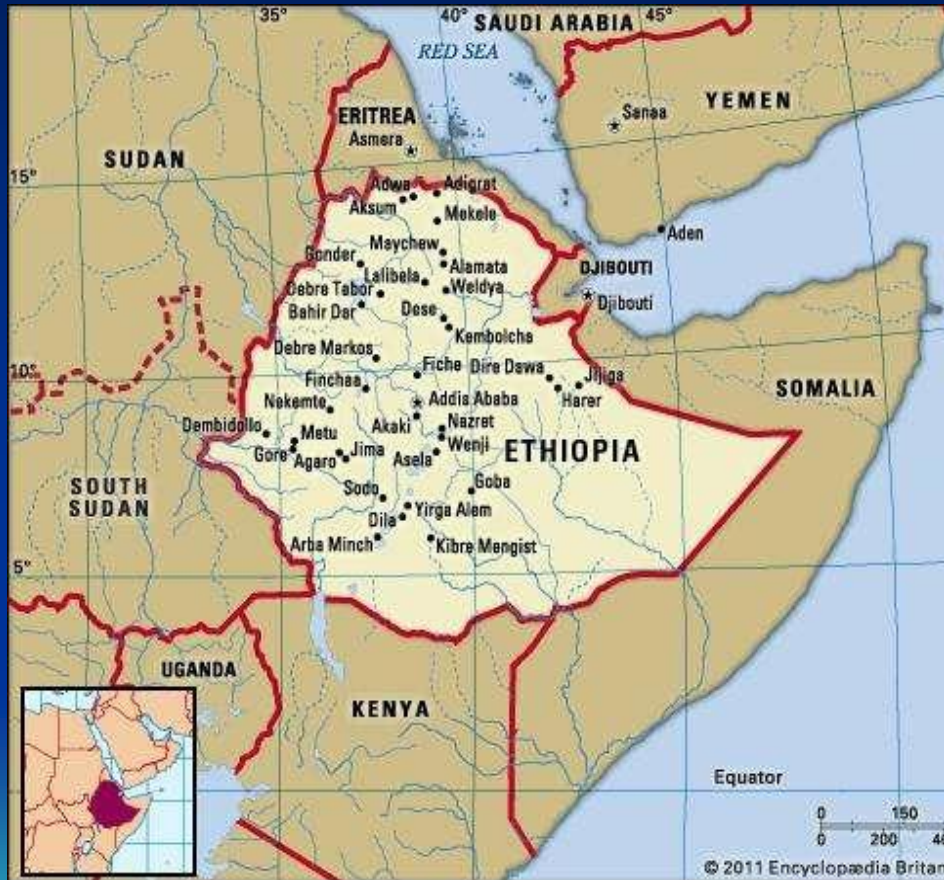- 9 sites in Gen'l Surgery
- 88 General Surgery graduates to date.
- Orthopedic Surgery (2)
- Pediatric Surgery (1)
- Head & Neck Surgery (1)
- Bongolo, Gabon, was the first PAACS training site.



The arrows show 8 of the PAACS training sites; the 9th (& newest) is in Egypt.

Ethiopia

- Ancient Christian culture
- Population 101,000,000 (82% rural)
- Presently 43% Orthodox Christian, 19% Protestant, 34% Muslim, & 4% other
- Literacy rate 49%
- Average lifespan 62 yrs.
- 30% live in poverty, 16% live on < \$1 per day.



Ethiopian surgical workforce

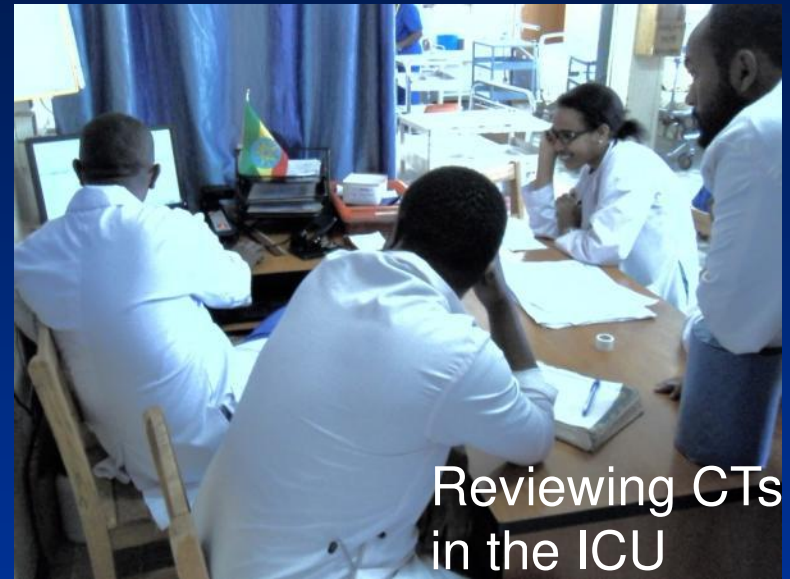
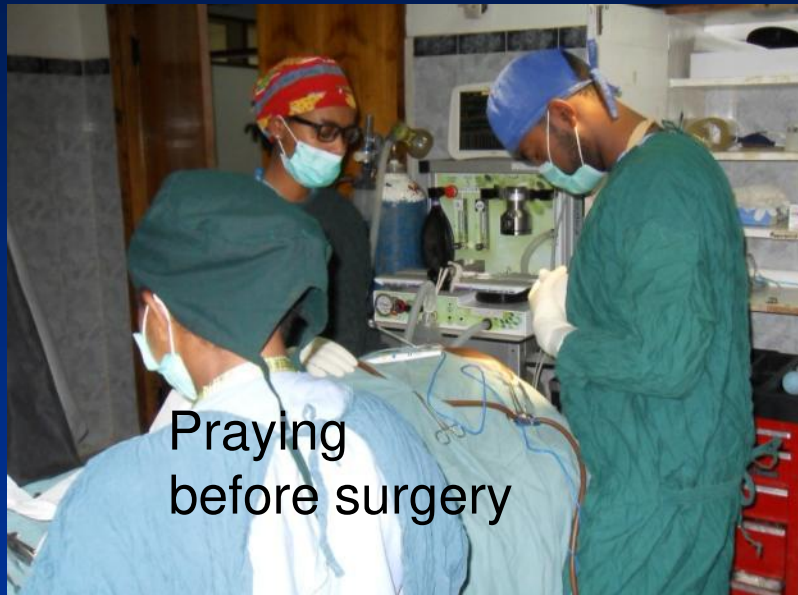- In USA, 7 GS/100,000 needed “to be adequate”
- In USA, 2012, 5.8 GS/100,000 & dropping.
--Physician's Weekly, 2012
- In Ethiopia, 3 GS/1,000,000 (roughly 300 General Surgeons in the country)
- Same ratio as having 1000 GS for the entire USA



Soddo Christian Hospital



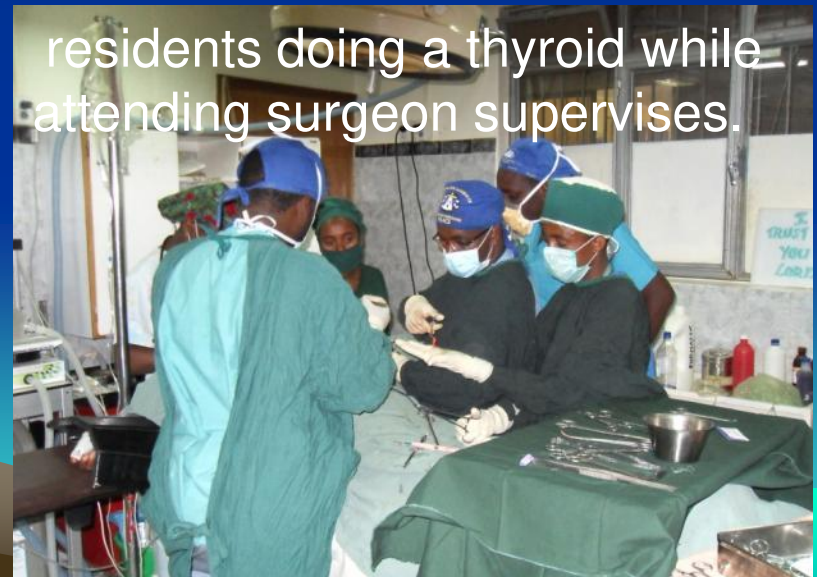PAACS Residents at Soddo



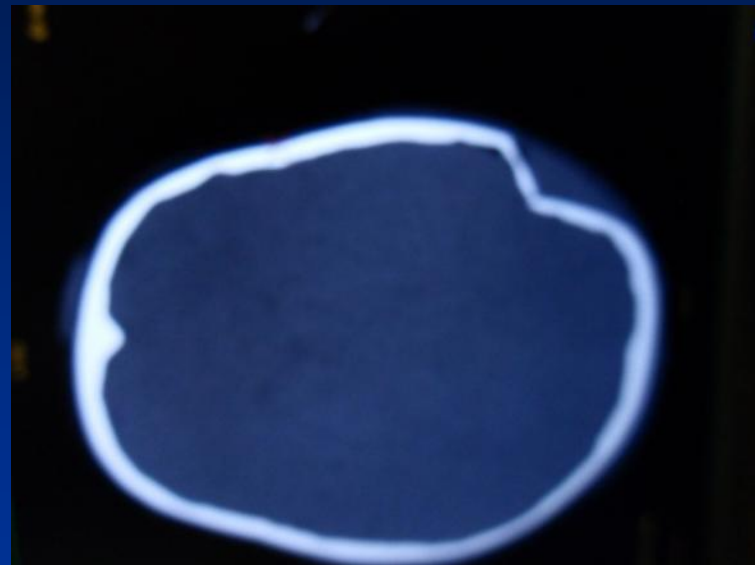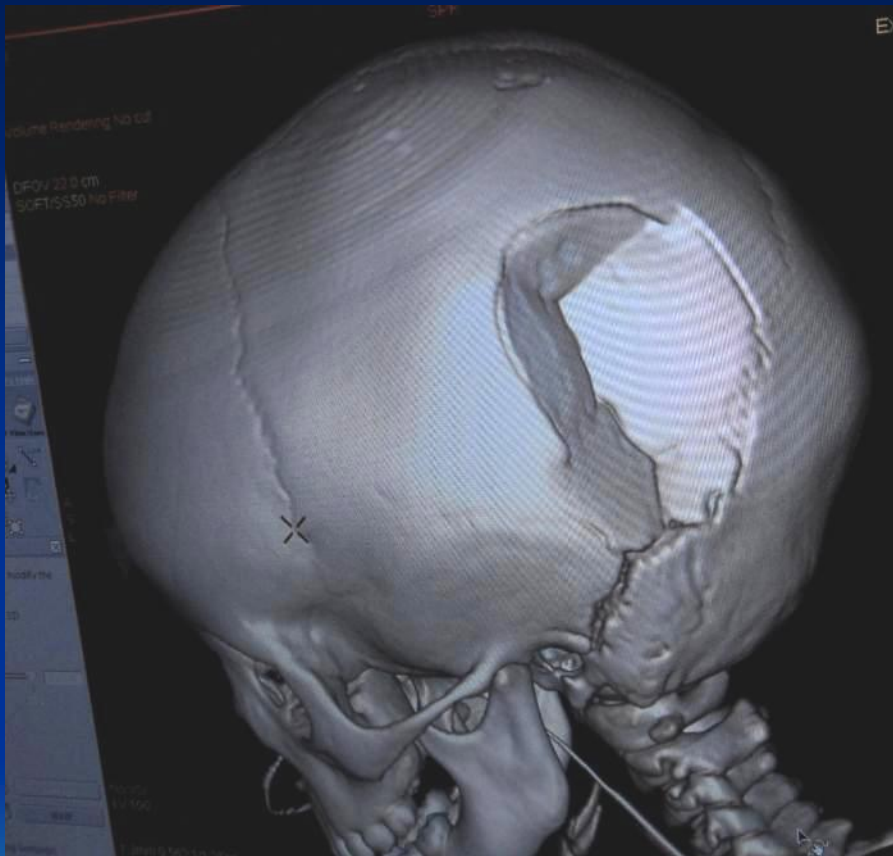
PAACS Residents II



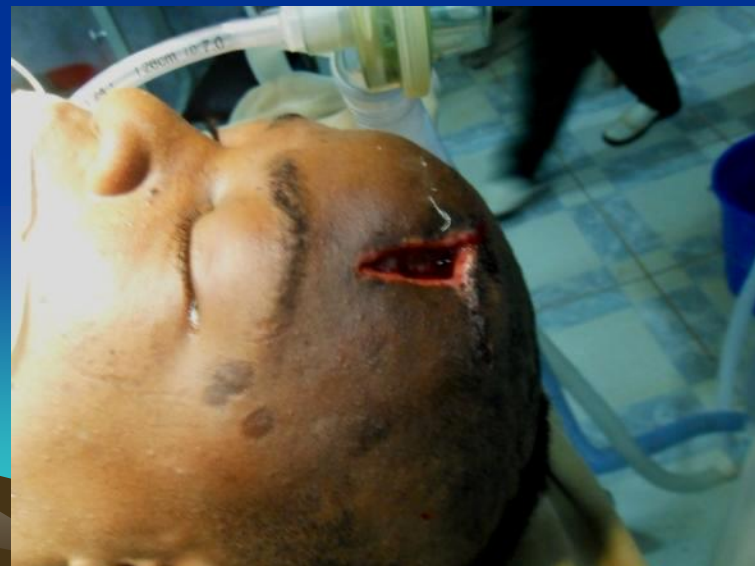Who's the old guy?



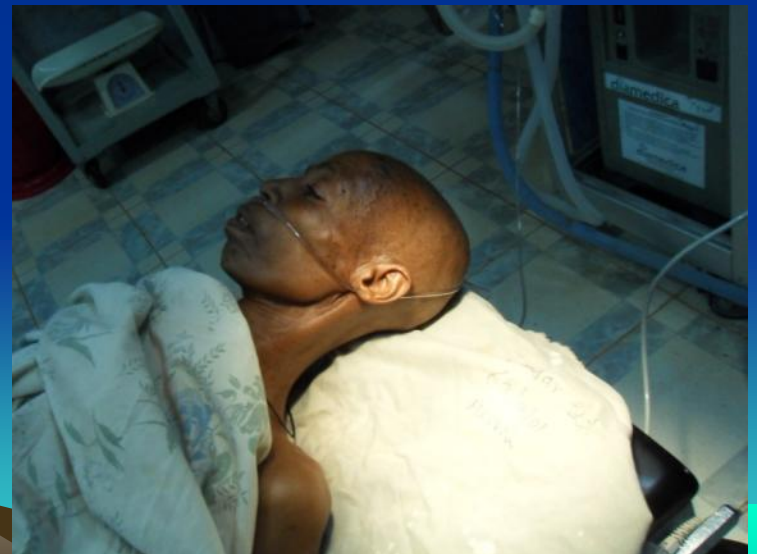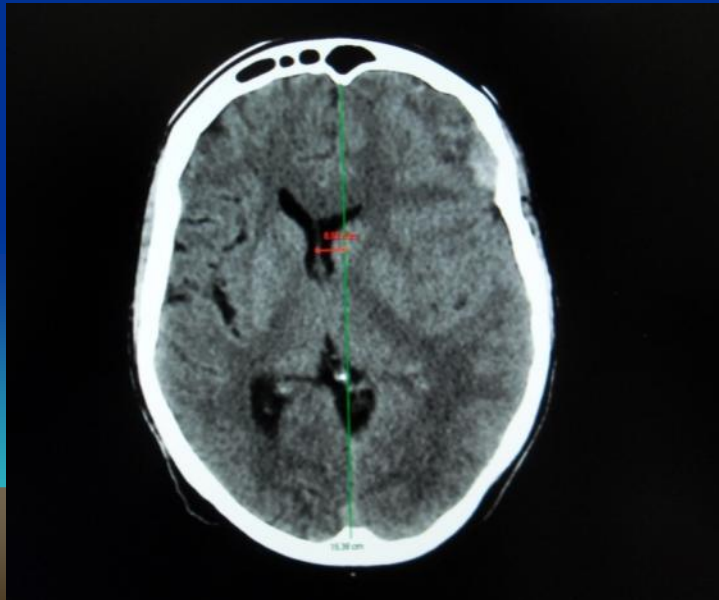
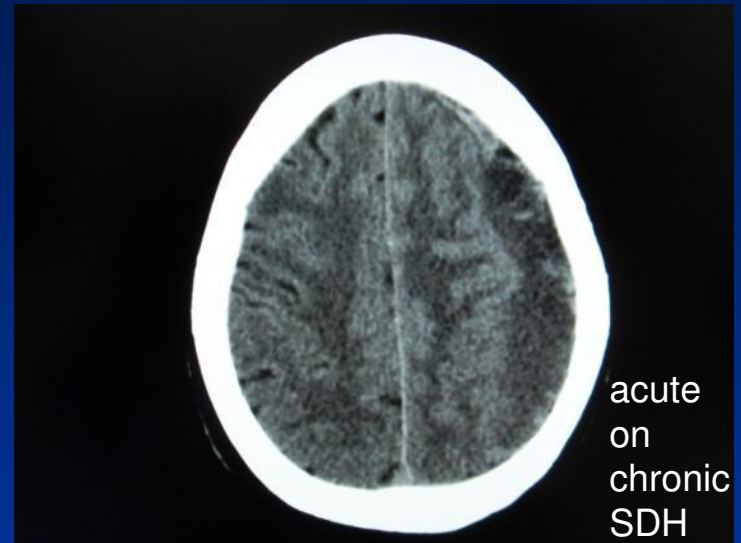
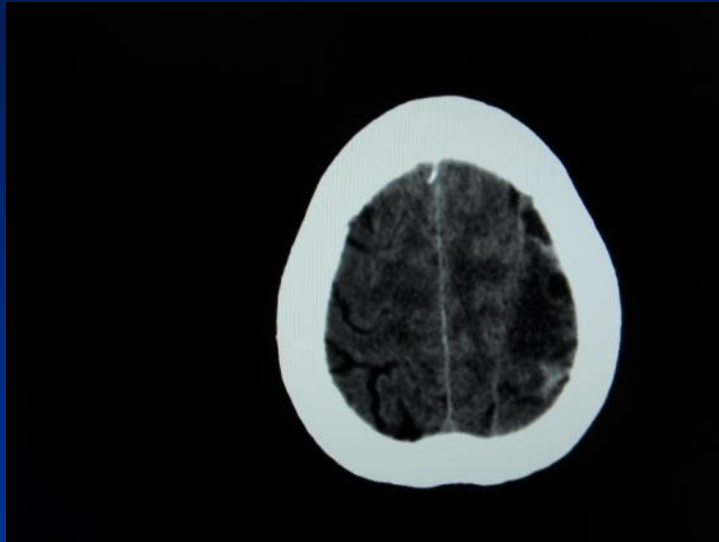
Head Injuries



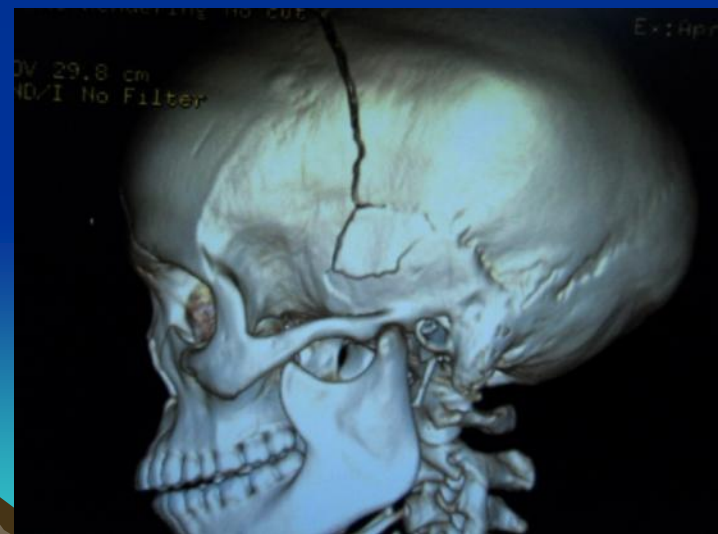
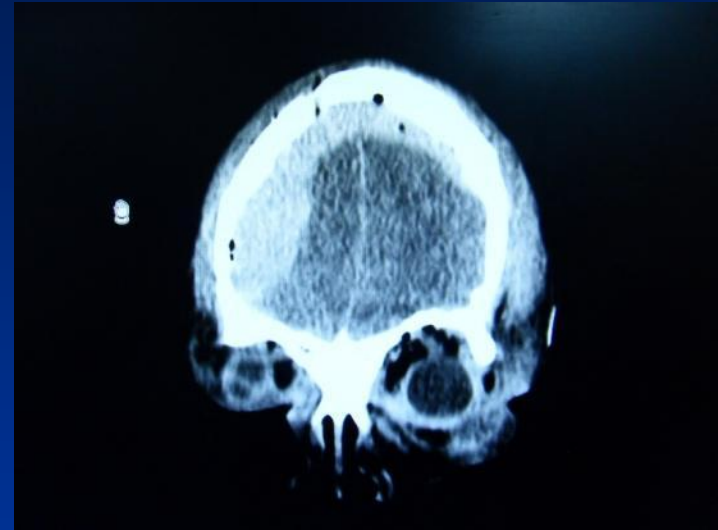
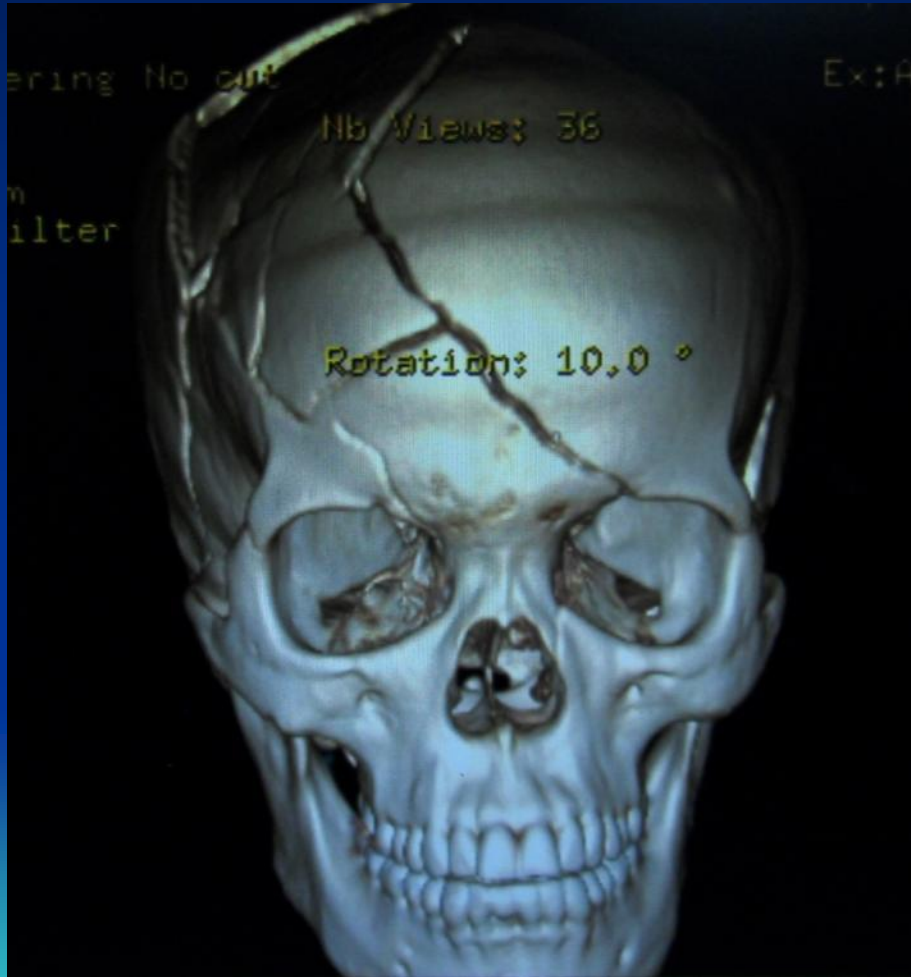
(different patients shown)



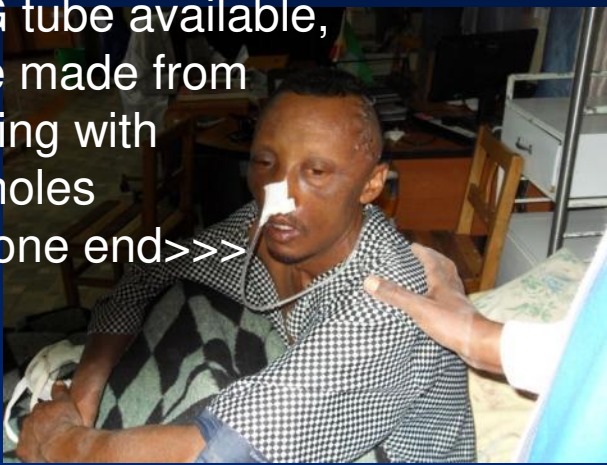One of many subdural hematomas



Skull fracture with epidural hematoma



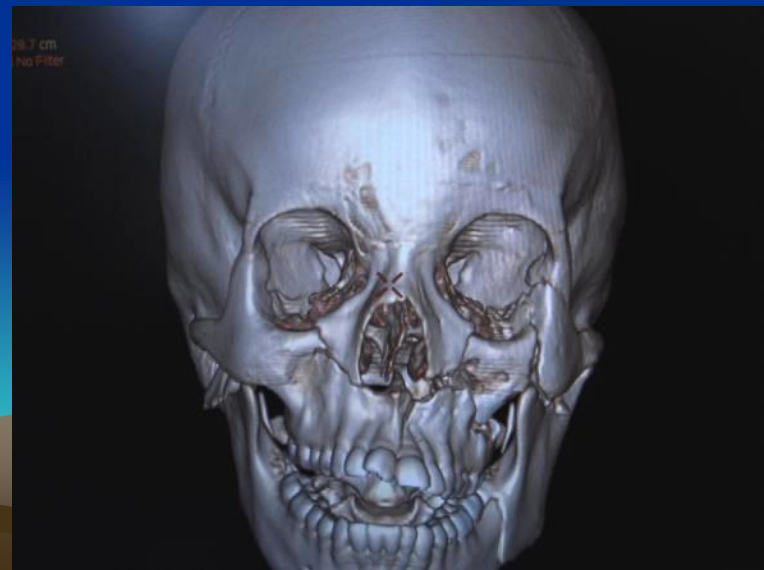
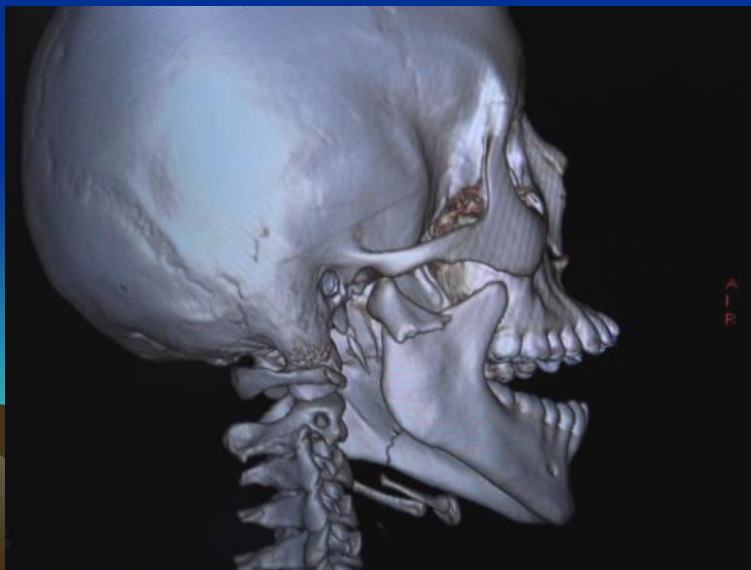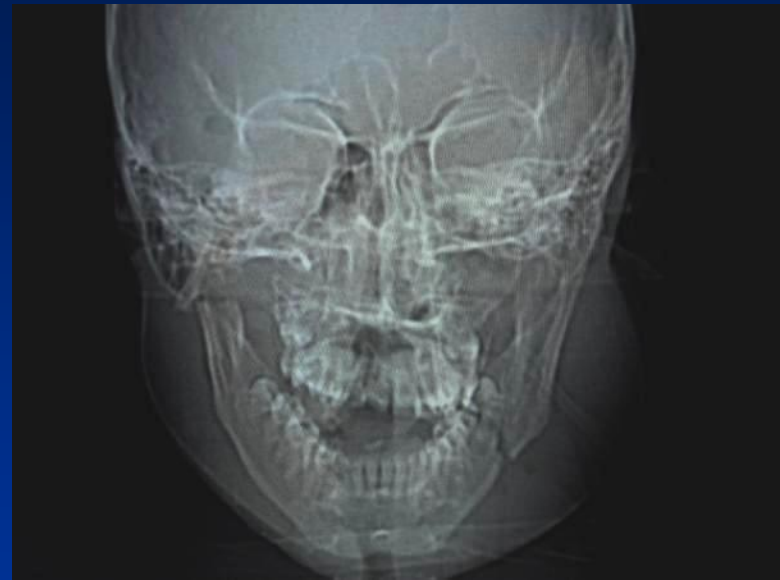
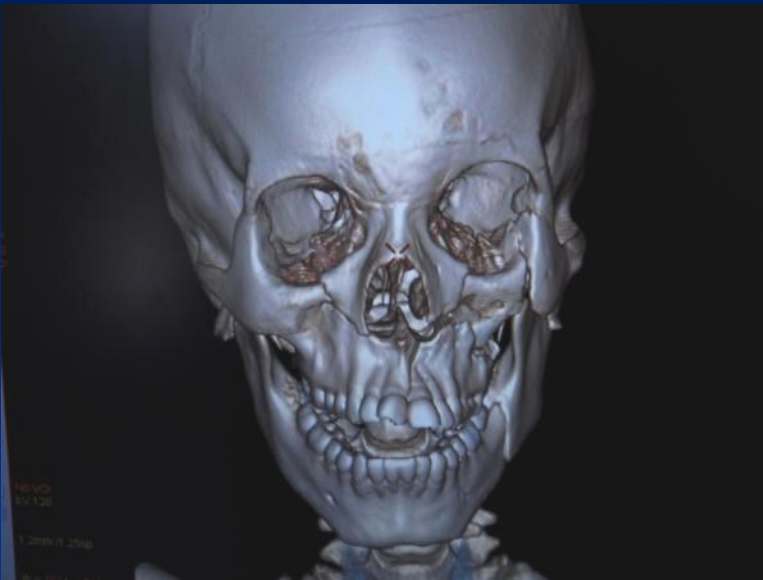No NG tube available,
so one made from
O₂ tubing with
extra holes
cut in one end>>>



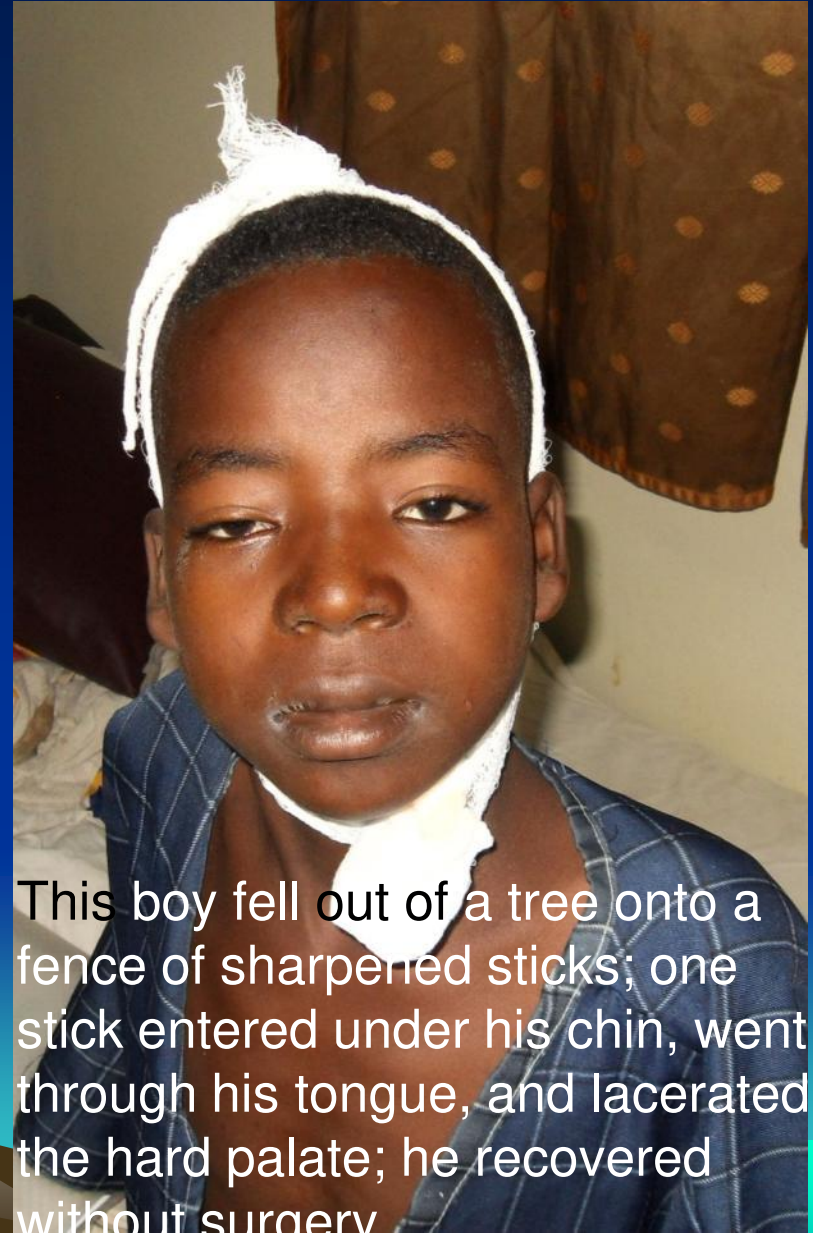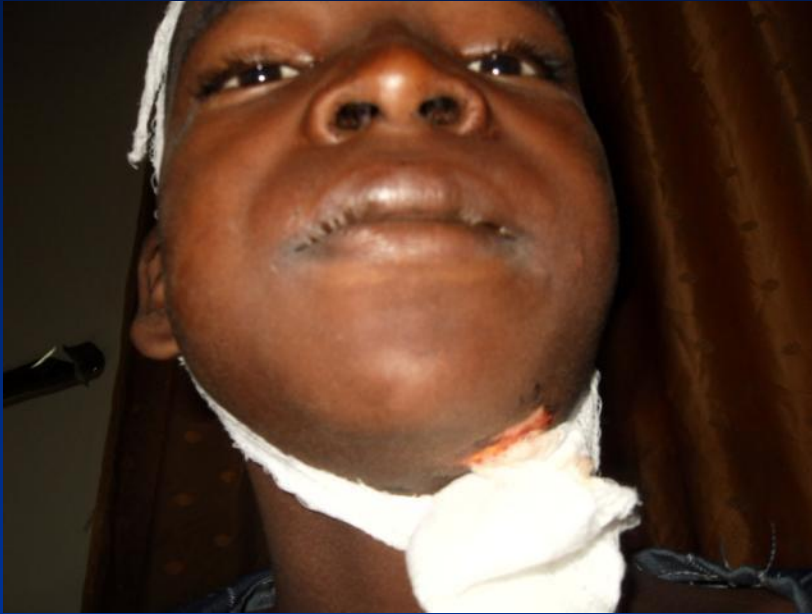Outcome of head trauma

- Timely surgical intervention **often** results in rapid improvement, but...complete recovery, if it occurs, may take months.
- Pt. is discharged to the care of family members when recovery plateaus & danger passes.
- Few long-term care facilities in the capital, none elsewhere ...families most often bear the lifelong burden.

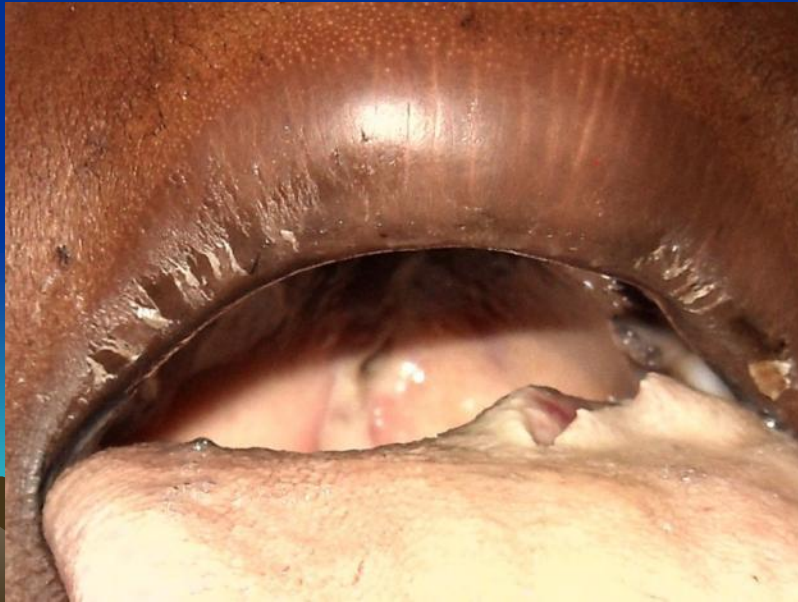Many complex facial fracture patients



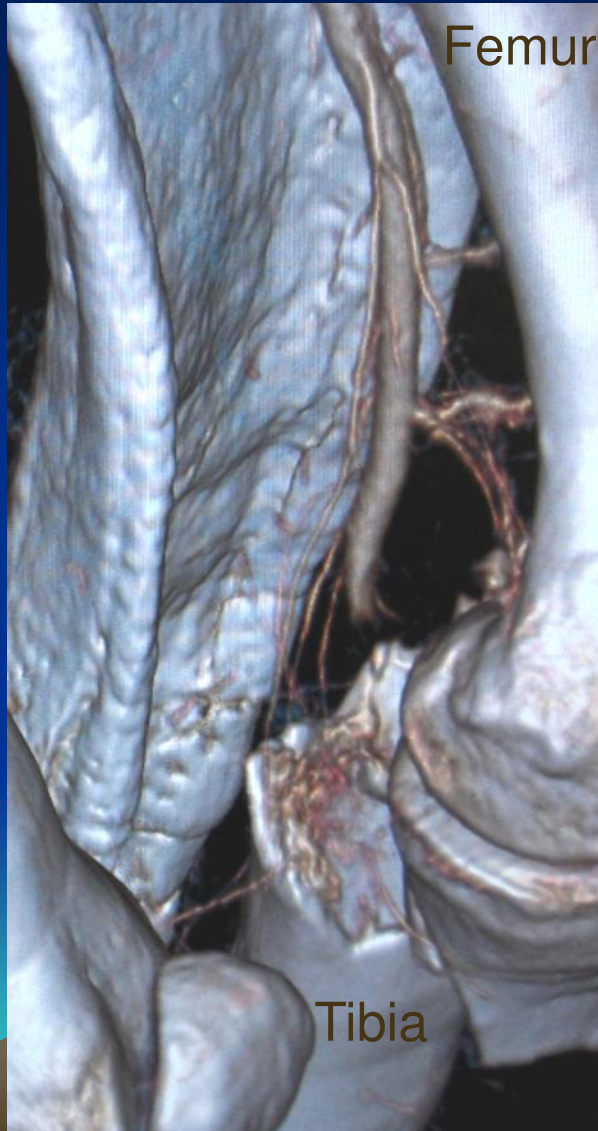God's mercy! Imagine this is your child!



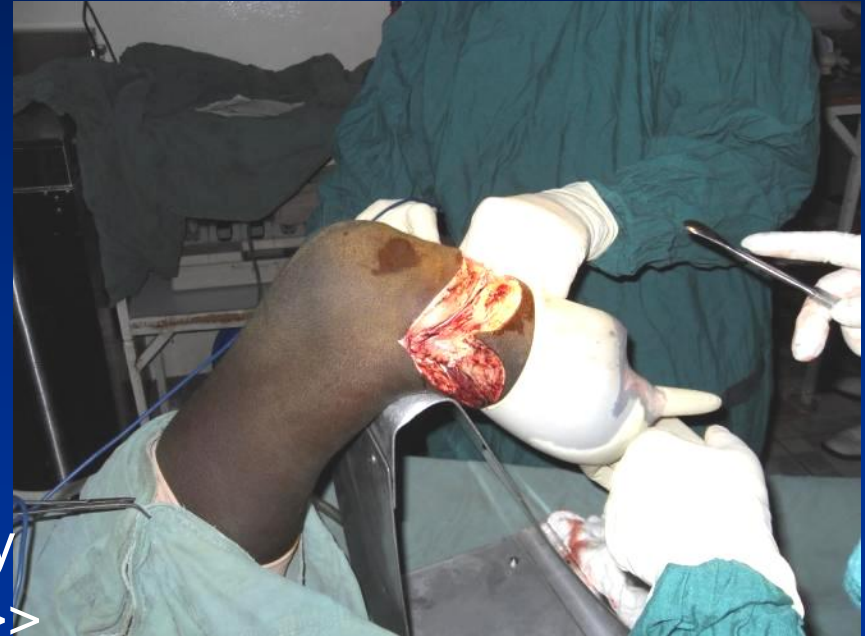This boy fell out of a tree onto a fence of sharpened sticks; one stick entered under his chin, went through his tongue, and lacerated the hard palate; he recovered without surgery.



Popliteal arteries often block with knee dislocations and very severe tibial fractures:

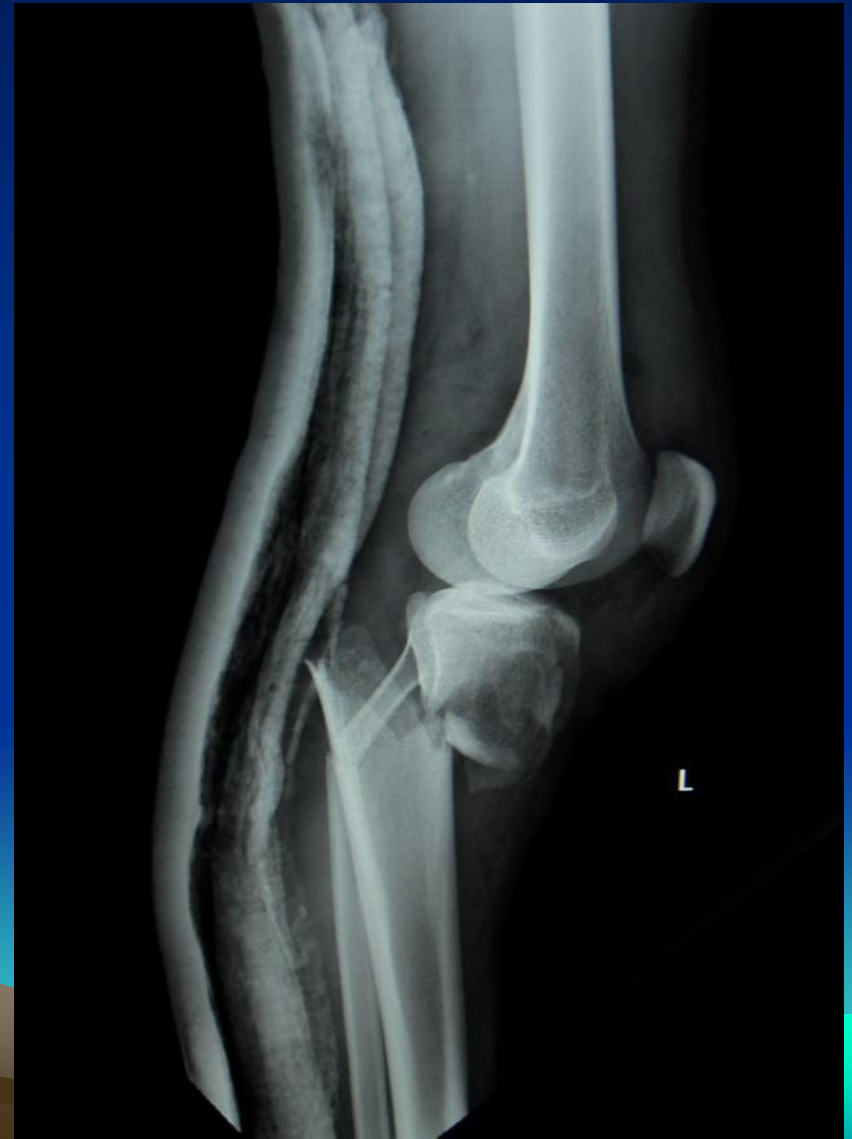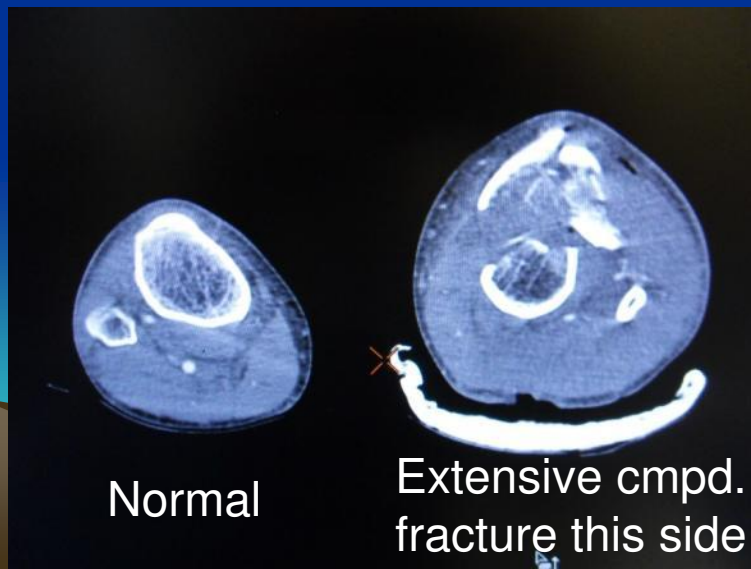
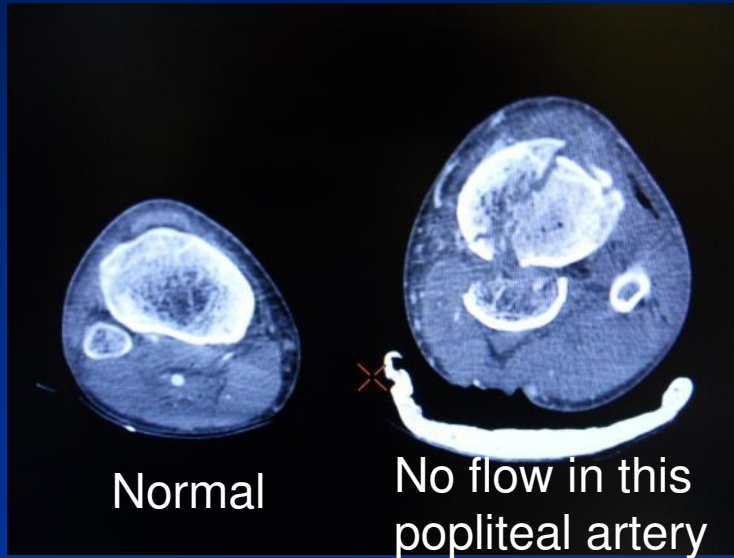


Injuries like
<<<<this...
...can easily
become>>>>

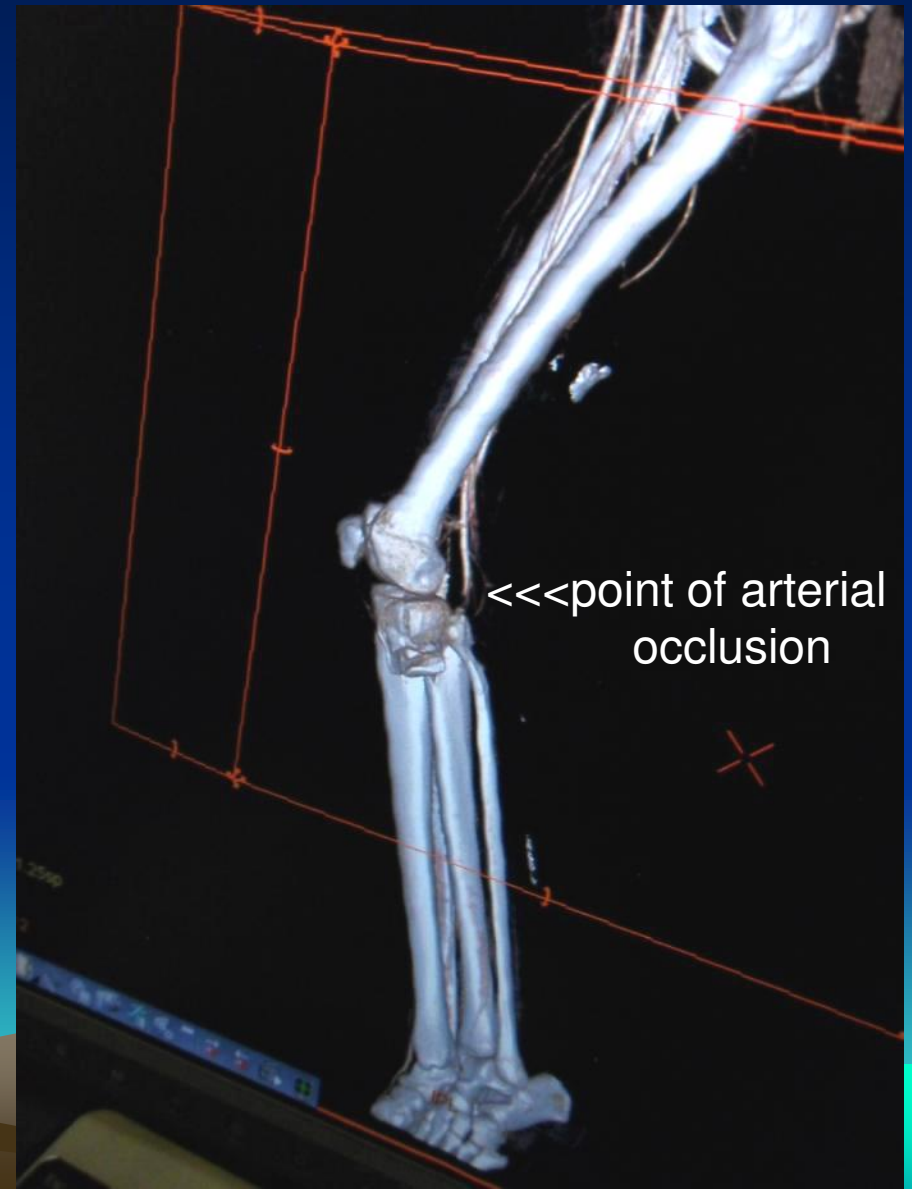
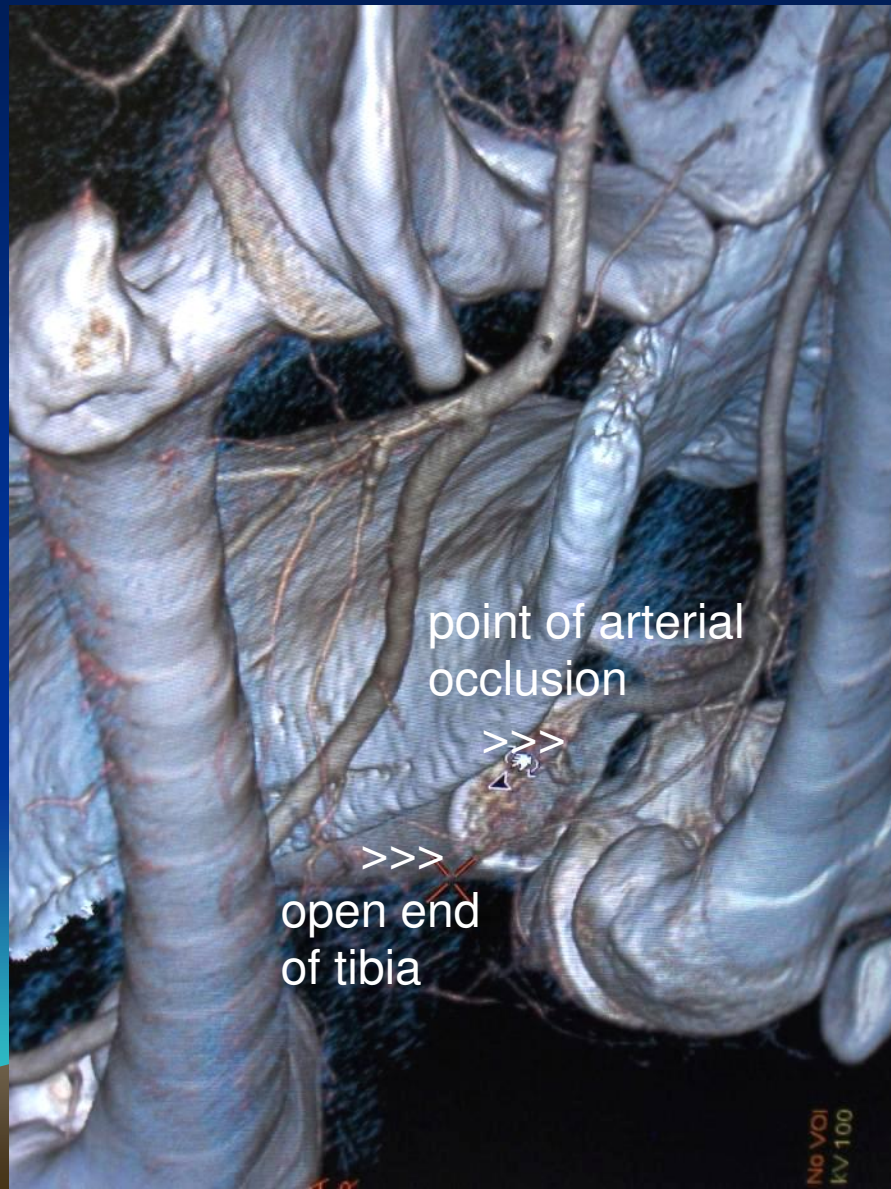


...an amputation...with very little chance in
Ethiopia of ever getting a prosthesis.

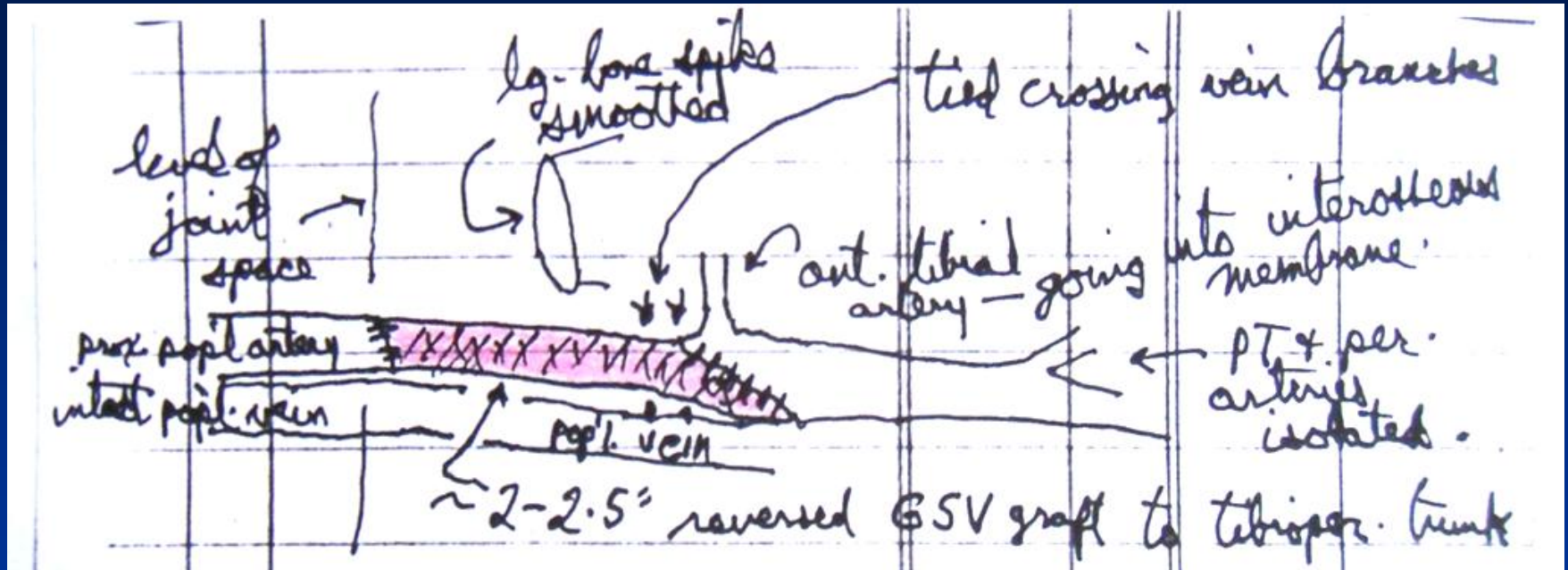
Our (God's) 'miracle' vascular patient, Jabesa



Jabesa's CT angiogram

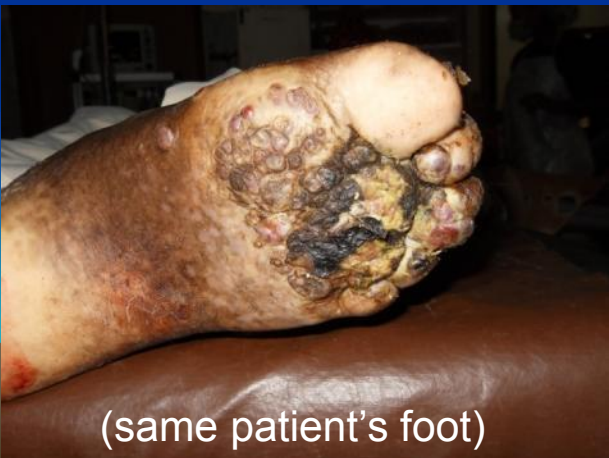
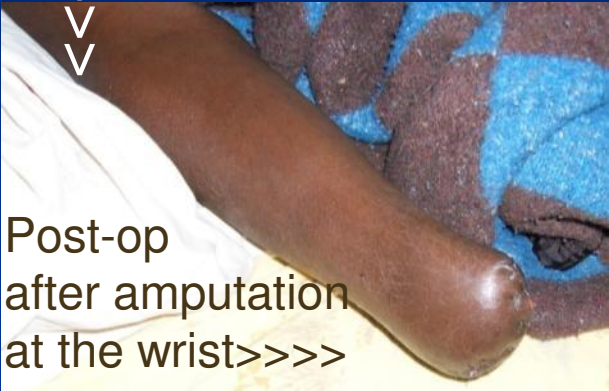
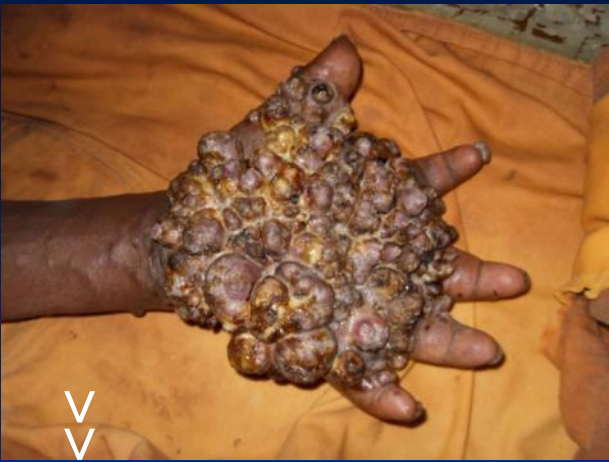Vein graft repair of Left Popliteal Artery

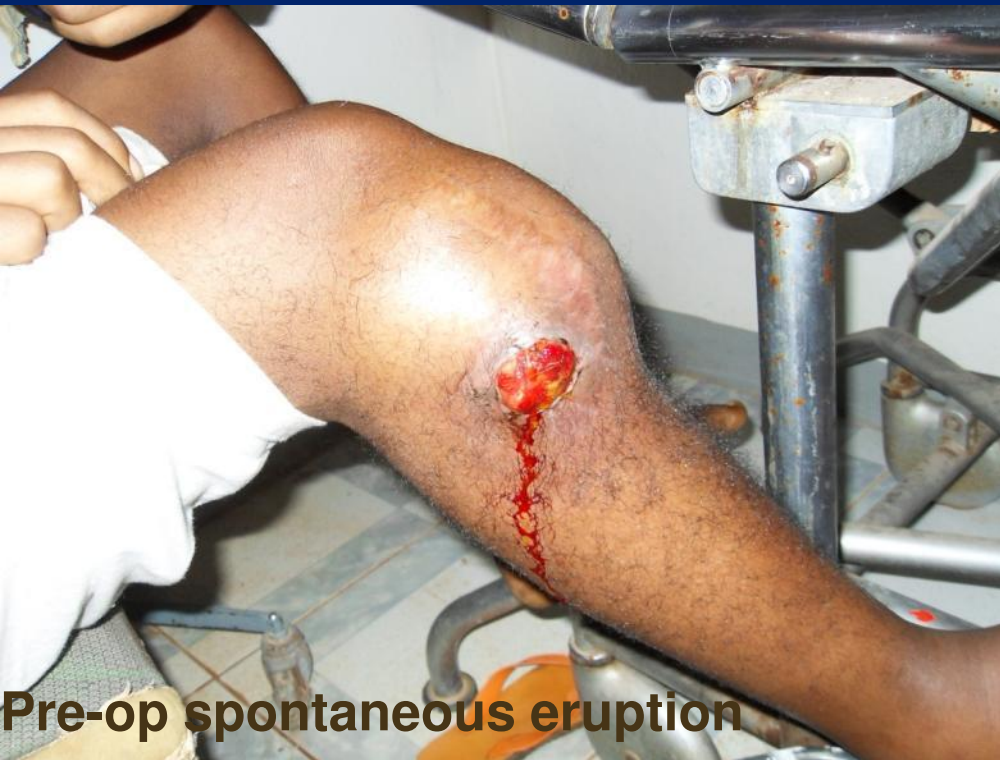

Madura foot (& hand)

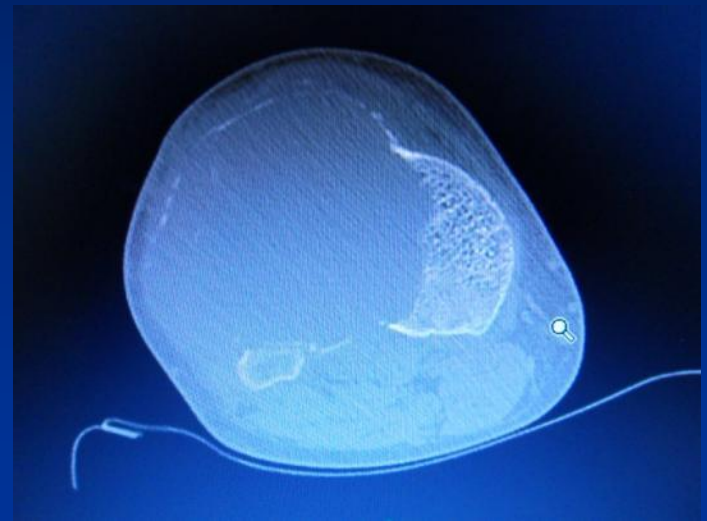
- Chronic granulomatous fungal disease seen in Africa, India, Central & South America.
- May follow thorn prick trauma.
- Extensive destruction of hand or foot bones.
- Actinomycetes type responds to antibiotics; eumycetes type often requires eventual amputation.



Huge giant cell tumor of tibia



Pre-op spontaneous eruption




Final outcome unknown at the time we left Soddo...

A walk around Soddo Christian Hospital




Bird life within the hospital



More birds of Ethiopia

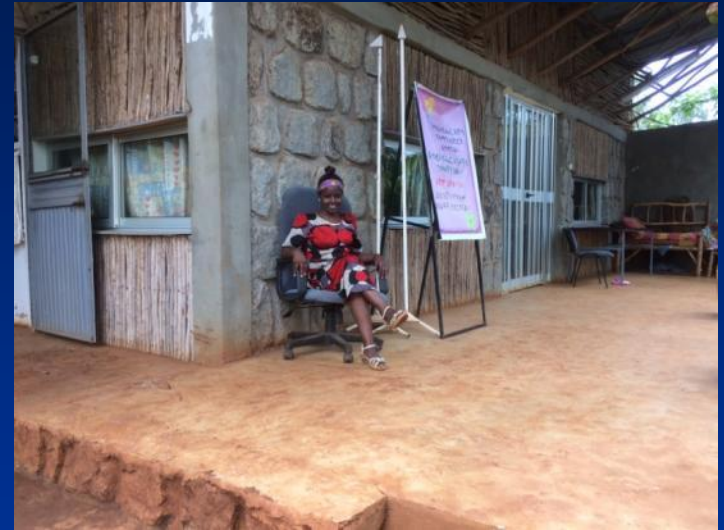

What was Adelaide doing there? Staying busy!



Taking the bajaj to
WRAPS every day

Working with the WRAPS staff



Adelaide's daily work with WRAPS

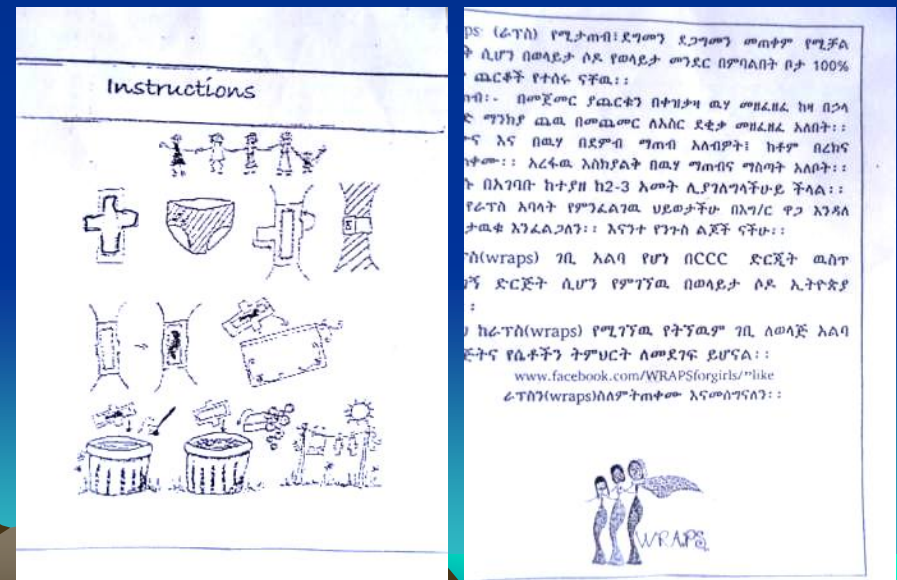


WRAPS means:
Washable
Re-usable
Affordable
PadS

The WRAPS products



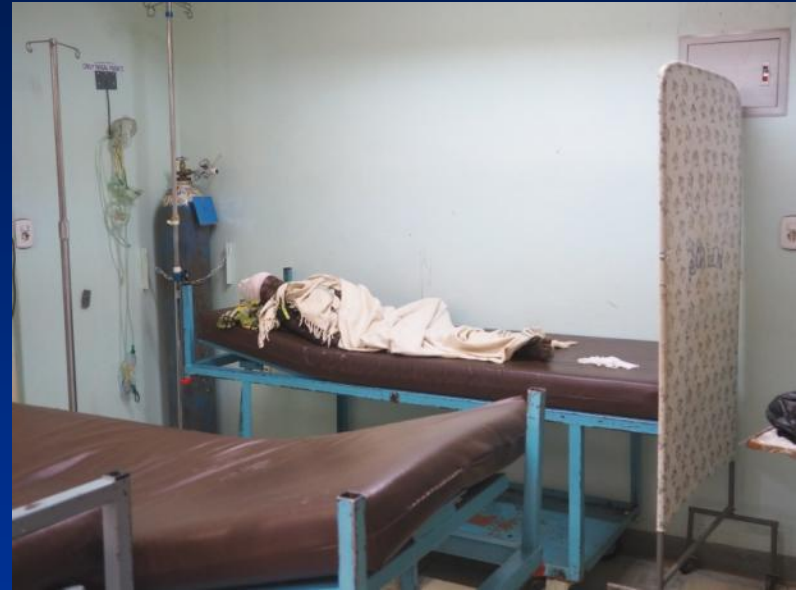What's inside a WRAPS kit



X ray, Pharmacy, and the Surgery Department



The E.R. and hospital “corridors”



Ancillary buildings within the hospital

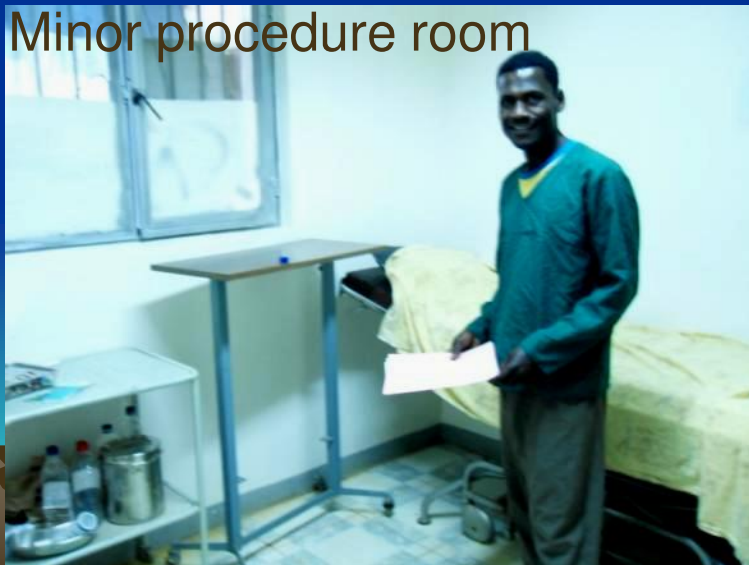
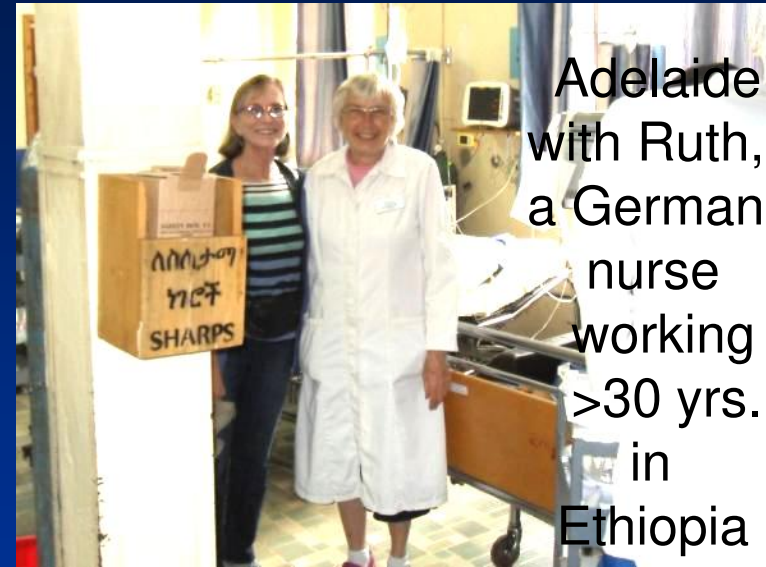
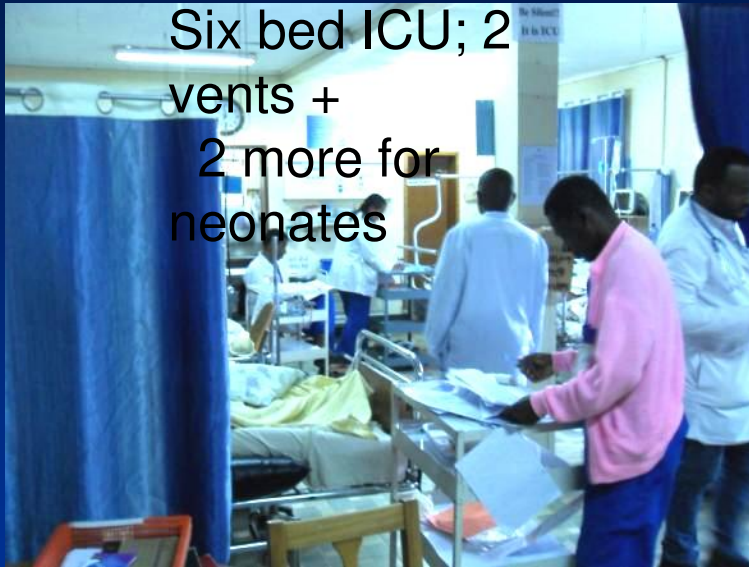Our Lord calming the storm...in the often chaotic Soddo E.R. waiting area

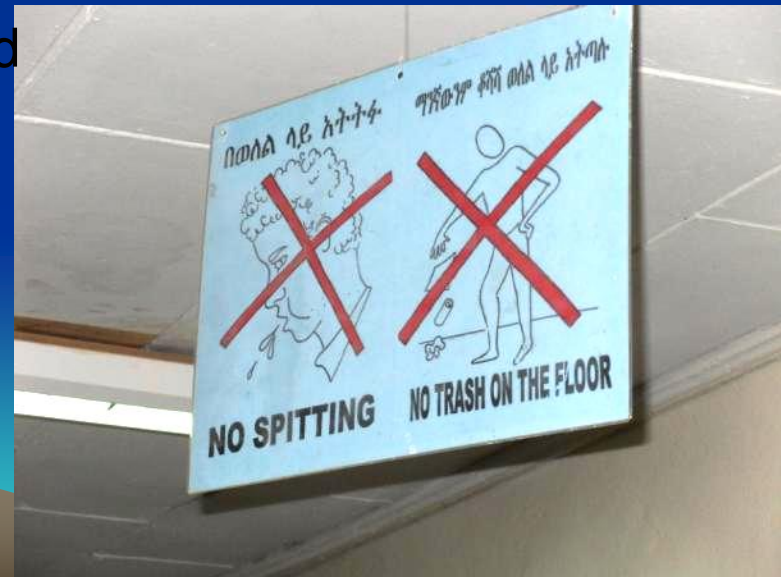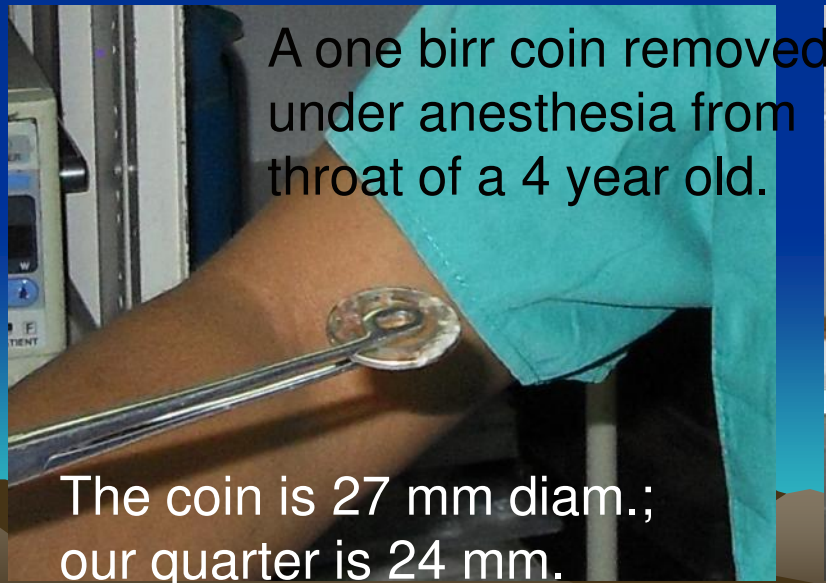

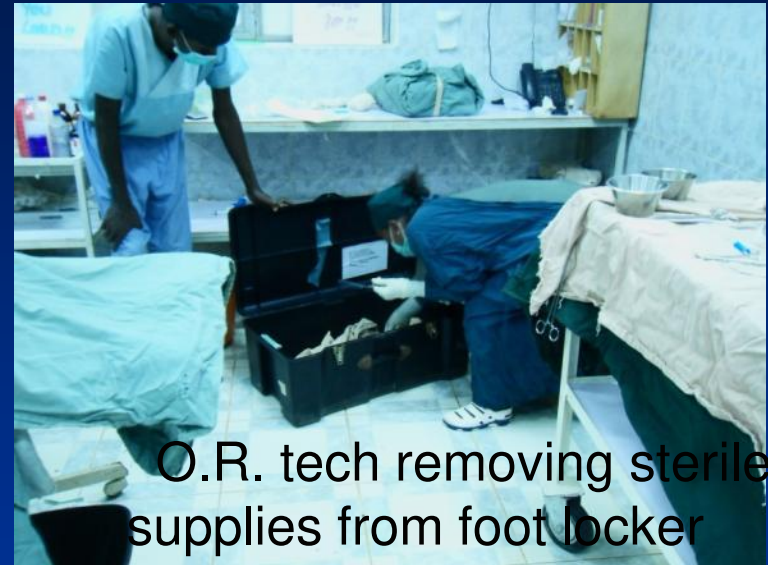
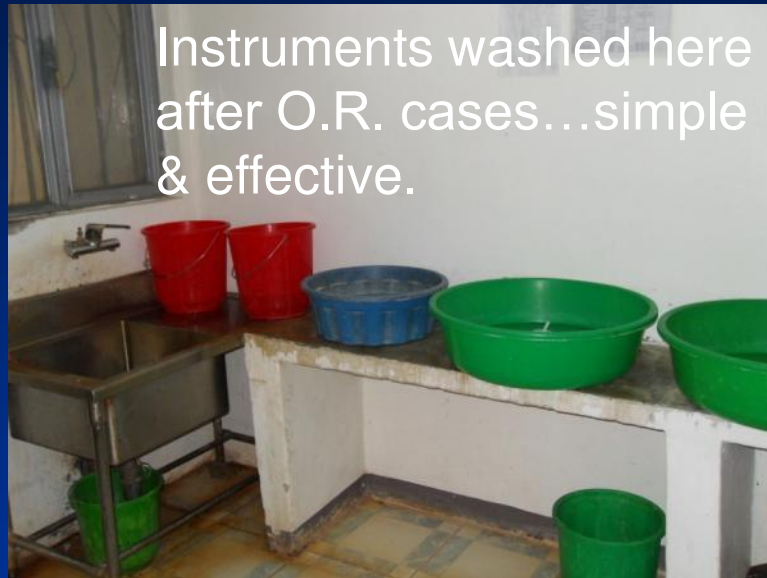Recounted in
Matthew 8,
Mark 4,
and Luke 8.

ICU, minor O.R., ward dressing cart



Unusual sights in the O.R.



Stay at the Paradise Lodge in Arba Minch



Mammals around the lodge



Lake Chamo wildlife



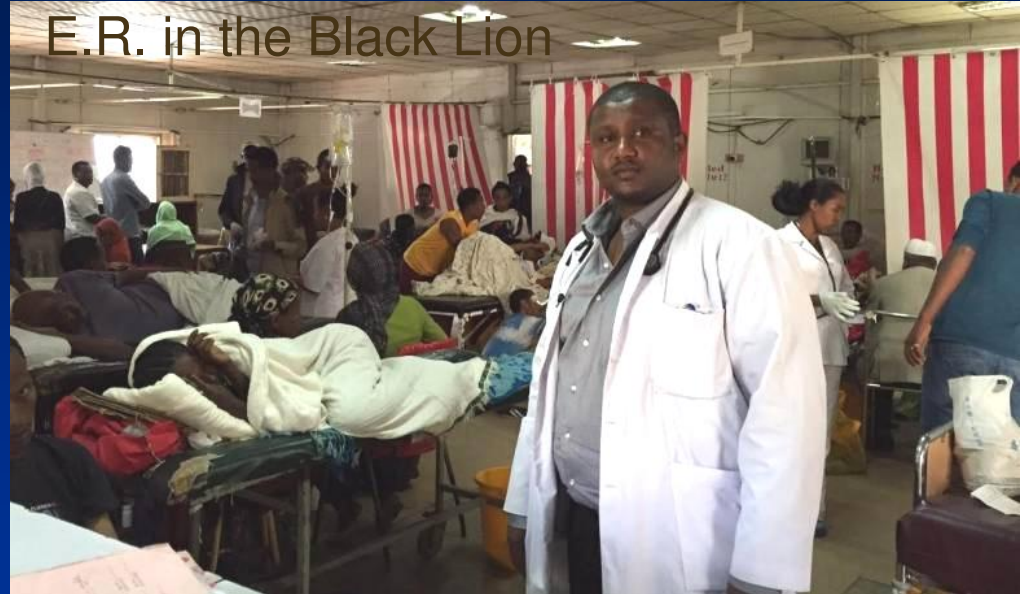Lake Chamo Rivals



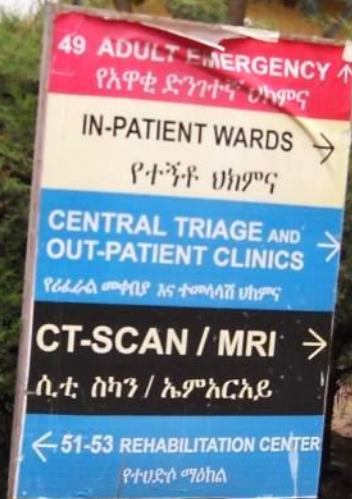Black Lion Hospital: the best in Ethiopia



E.R. in the Black Lion



Teaching ward rounds in the Black Lion



In conclusion...we ask ourselves:



- Is it fair that some have so much & some so little?
- Does the bible teach that life is (or should be) fair?
- What does God expect of you? ...of me?
- Spend time listening for God's plan for your life.
- How would He then have us act? Each of us must determine this for ourselves.

Contact information

To inquire about serving with World Medical Mission/Samaritan's Purse:

Phone: 828-262-1980

Website:

www.samaritanspurse.org/medical/serve-with-world-medical-mission/



Questions?

The King will reply, 'I tell you the truth, whatever you did for one of the least of these brothers of mine, you did for me.'

Matthew 25:40



Soddo, Ethiopia




Walking around in Soddo



Walking from 'our house' to the hospital



Our living quarters (courtesy of the chiefs of surgery & medicine)

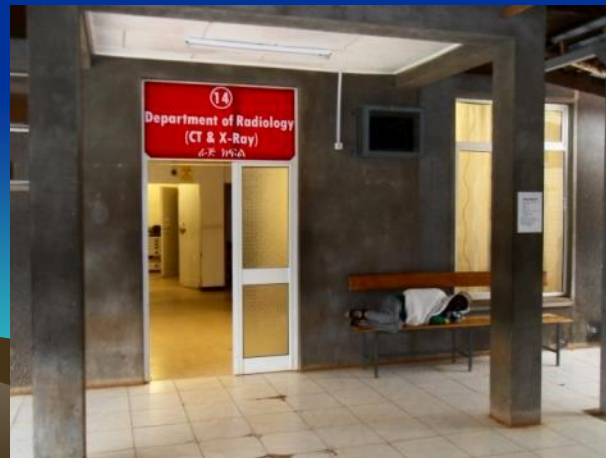

Ethiopian insect life



One day the giant termites hatched... thousands of them...

Dropped wings scattered over the floor
of the X ray department



This one was walking
around with one wing
still attached...



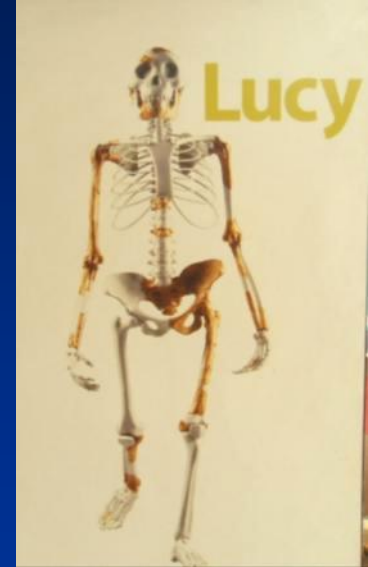Boat tour of Lake Chamo



Forty Springs wildlife



National Ethiopian Museum & Lucy



Ardi



- 4.4 million years old?
- Walked upright?
- Most complete early hominid specimen, 125 bones, female.
- Discovered in 1994.
- Presently called genus *Ardipithecus*, thought to precede both *Homo* and *Australopithecus* (Lucy).

Haile Selassie, Emperor of Ethiopia from 1930-1974



Bird life right outside our door



Getting around in Soddo—the bajaj

Adelaide took a bajaj to work 5 days a week, a 15 minute ride; Melchius was her regular driver: slow & safe.



Traffic was the most dangerous thing in Soddo; much of the work of the SCH surgical department was dealing with the results of vehicle-vehicle and vehicle-pedestrian collisions.